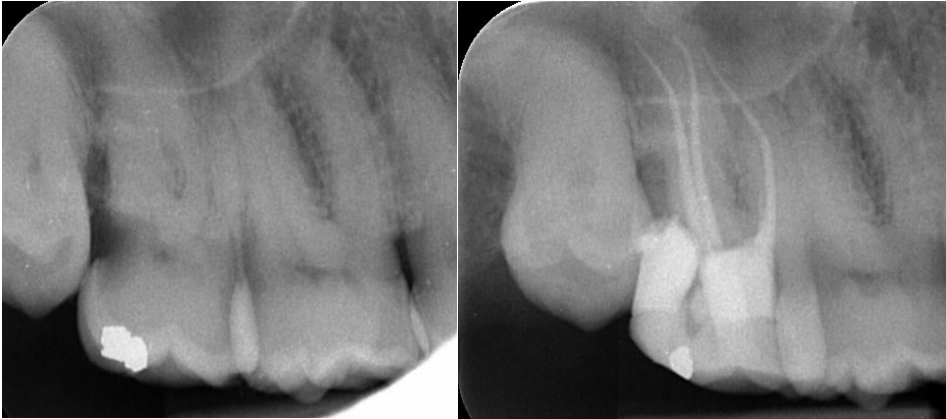
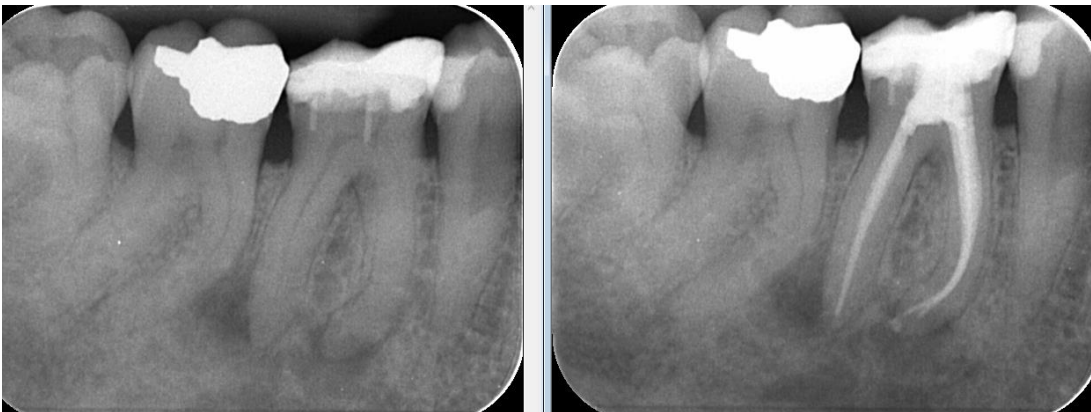
Post Lockdown Endodontics

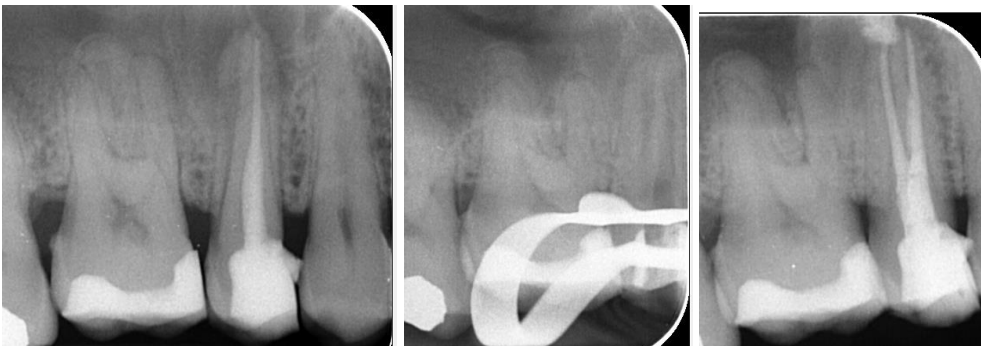
Adapting to the new FFP3 half masks!



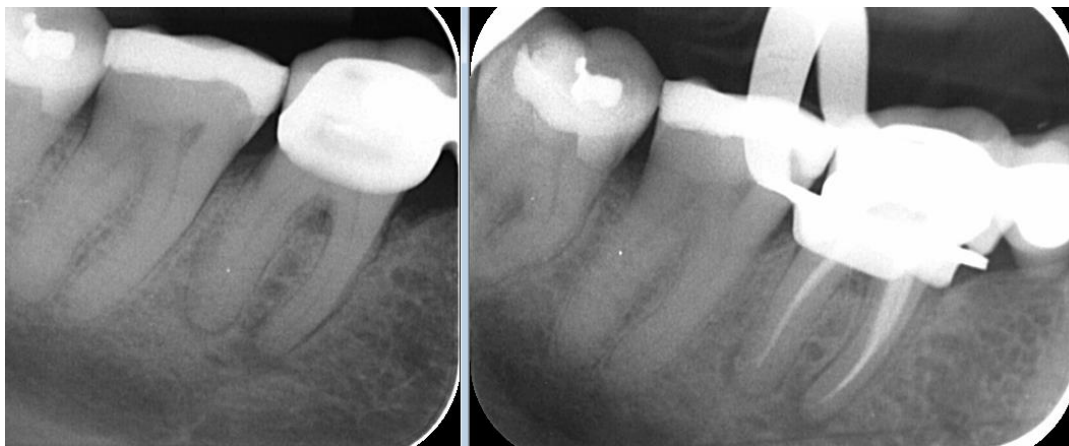Subgingival caries 17, SDR pre endo restoration and then RCT



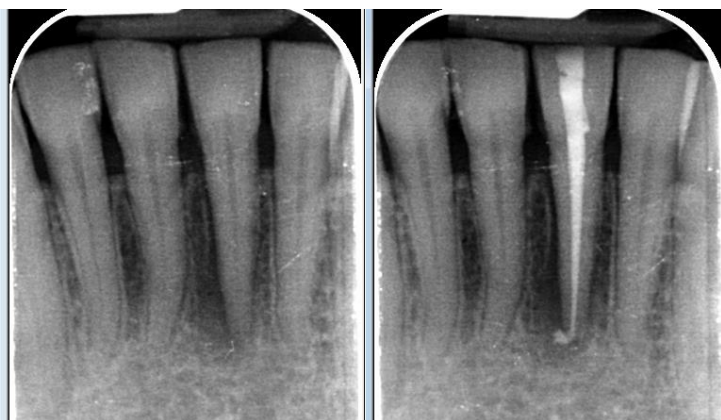
RCT 46 with composite dowel in canal orifices



Re-RCT, missed palatal canal located, old GP removed, obturation with bioceramic sealer



RCT through bridge abutment 46



31 RCT Thankfully much speedier than the molars!